

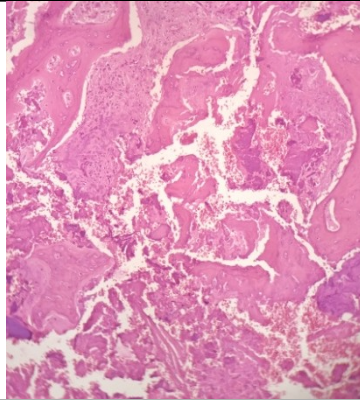
Patient Name	Mr. DINESH KUMAR	Client Name	Vedic Hospital,	Specimen Received	25-Mar-2019
Age/Sex	40/M		Gurgaon	Specimen Type	Tissue
Patient ID	011903250190	Client Code	MolQ1492CM	Collection Date	25-Mar-2019
Specimen ID	MOLQ/B-501-19	Ref. Doctor	LIFE CARE CLI LAB OPD	Report Date	29-Mar-2019

SURGICAL PATHOLOGY REPORT

Osteomyelitis (2nd Right Foot)

DIAGNOSIS

ACUTE OSTEOMYELITIS



SPECIMEN

Osteomyelitis (2nd Right Foot)

GROSS

Received multiple greyish white tissue piece.
E/A

Microscopy

1. Section examined shows bony trabeculae with osteocytes. Section also shows calcified tissue, inflammatory cells (lymphocytes and polymorphs) suggestive of sequestrum.
2. No malignant cells and no granuloma seen.

Note : All biopsy specimen will be stored for 15 (fifteen) days, block and slides for 5 (five) years only from the time of receipt at the laboratory. No request, for any of the above, will be entertained after the due date.

Reference

- i) Rosai and Ackerman's Surgical Pathology.
- ii) Modern Surgical Pathology.

Gulshan Yadav, MD
Consultant Pathologist