

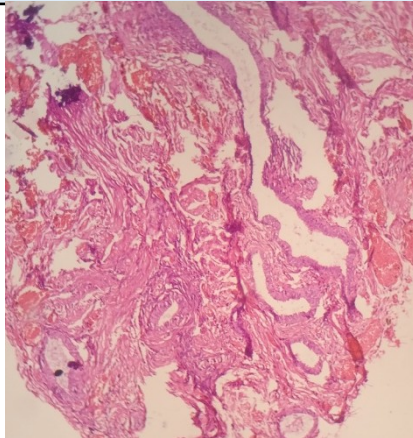
Patient Name	SUHAIB ALOOSA	Client Name	Bandipora Collection	Specimen Received	20/03/2019
Age/Sex	31 YRS/M		Centre, Jammu & Kashmir	Specimen Type	Tissue
Patient ID	011903180435	Client Code	MolQ1929P	Collection Date	20/03/2019
Specimen ID	MOLQ/B-476/19	Ref. Doctor	DR ISHFAQ	Report Date	28/03/2019

SURGICAL PATHOLOGY REPORT

Polypectomy

DIAGNOSIS

INFLAMMATORY POLYP



SPECIMEN

Polypectomy

GROSS

Received 1x1.2 cm greyish white tissue piece.

Microscopy

- Section examined shows mucosal lining epithelium having columnar cells with round to oval nucleus with sub mucosal glands, large number of blood vessels, inflammatory cells (lymphocytes).

Note : All biopsy specimen will be stored for 15 (fifteen)days, block and slides for 5(five) years only from the time of receipt at the laboratory. No request ,for any of the above ,will be entertained after the due date.

Reference

- Rosai and Ackerman's Surgical Pathology.
- Modern Surgical Pathology.

Gulshan Yadav, MD
Consultant Pathologist