

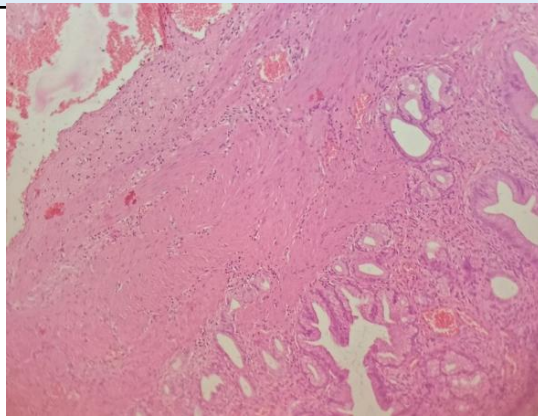
Patient Name	Ms. SHAHIDA 8120	Client Name	Patients Care Clinical	Specimen Received	23/03/2019
Age/Sex	40 Years/Female		Laboratory, Jammu & Kashmir	Specimen Type	Tissue
Patient ID	011903230086	Client Code	MolQ1839P	Collection Date	23/03/2019
Specimen ID	MOLQ/B-486/19	Ref. Doctor		Report Date	26/03/2019

SURGICAL PATHOLOGY REPORT

GALL BLADDER.

DIAGNOSIS

CHOLECYSTITIS



SPECIMEN

Gall Bladder.

GROSS

Received 6.5x2.8 cm long gall bladder. Cut section shows no stones.

Microscopy

- Section examined shows ulcerative mucosa and Rokitansky Aschoff sinuses (irregularly shaped tubular structures lined by cuboidal lining epithelium with round to oval nucleus) with fibro collagenous tissue and inflammatory cells (lymphocytes).

Note : All biopsy specimen will be stored for 15 (fifteen) days, block and slides for 5 (five) years only from the time of receipt at the laboratory. No request, for any of the above, will be entertained after the due date.

Reference

- Rosai and Ackerman's Surgical Pathology.
- Modern Surgical Pathology.

Gulshan Yadav, MD
Consultant Pathologist