

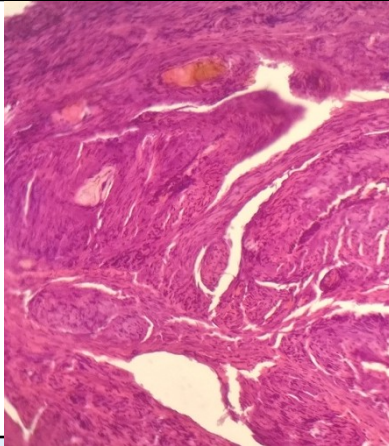
Patient Name	Mr. JAI NARYAN	Client Name	Pushpanjali Hospital (Rewari)	Specimen Received	22/03/2019
Age/Sex	60 YRS/M	Client Code	MolQ1789CM	Specimen Type	Tissue
Patient ID	011903220285	Ref. Doctor	DR KULDEEP	Collection Date	22/03/2019
Specimen ID	MOLQ/B-482/19			Report Date	28/03/2019

SURGICAL PATHOLOGY REPORT

Pre-Pyloric Gastric Perforation

DIAGNOSIS

GRANULATION TISSUE



SPECIMEN

Pre-Pyloric Gastric Perforation

GROSS

Received 2.5x0.5 cm greyish white tissue piece.

Microscopy

1. Section examined shows submucosal glands surrounded by stromal cells with mild reactive atypia and inflammatory cells.
2. No malignant cells and no granuloma seen.

Note : All biopsy specimen will be stored for 15 (fifteen) days, block and slides for 5 (five) years only from the time of receipt at the laboratory. No request, for any of the above, will be entertained after the due date.

Reference

- i) Rosai and Ackerman's Surgical Pathology.
- ii) Modern Surgical Pathology.

Gulshan Yadav, MD
Consultant Pathologist