

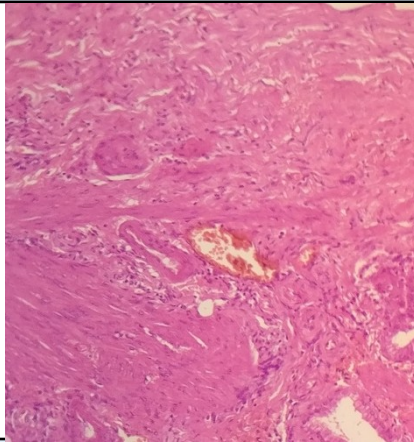
Patient Name	Mr. FAKRUDIN	Client Name	Global Diagnostic Center,	Specimen Received	22/03/2019
Age/Sex	41 YRS/M		Tauru	Specimen Type	Tissue
Patient ID	011903220254	Client Code	MolQ1703P	Collection Date	22/03/2019
Specimen ID	MOLQ/B-480/19	Ref. Doctor		Report Date	28/03/2019

SURGICAL PATHOLOGY REPORT

Cyst ?

DIAGNOSIS

BENIGN LESION



SPECIMEN

Cyst ?

GROSS

Received two greyish white tissue pieces measuring 3x1.9 cm, 1x1 cm

Microscopy

1. Section examined shows mature adipose cells and fibrocollagenous tissue only.
2. No malignant and no granuloma seen.

Note : All biopsy specimen will be stored for 15 (fifteen)days, block and slides for 5(five) years only from the time of receipt at the laboratory. No request ,for any of the above ,will be entertained after the due date.

Reference

- i) Rosai and Ackerman's Surgical Pathology.
- ii) Modern Surgical Pathology.

Gulshan Yadav, MD
Consultant Pathologist