

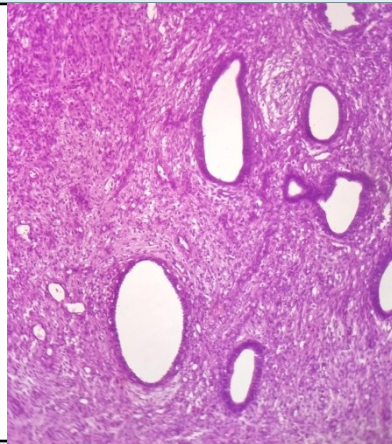
| | | | | | |
|---------------------|----------------|--------------------|--------------------------|--------------------------|------------|
| Patient Name | Ms. MUNNI DEVI | Client Name | Lalita Memorial Hospital | Specimen Received | 20/03/2019 |
| Age/Sex | 50YRS/F | | Pvt. Ltd. (Rewari) | Specimen Type | Tissue |
| Patient ID | 011903190285 | Client Code | MolQ1652P | Collection Date | 20/03/2019 |
| Specimen ID | MOLQ/B-468/19 | Ref. Doctor | C/O LMH REWARI | Report Date | 28/03/2019 |

SURGICAL PATHOLOGY REPORT

Cervical Polyp

DIAGNOSIS

ENDOCERVICAL POLYP



SPECIMEN

Cervical Polyp

GROSS

Received 4x2.5cm greyish white tissue piece.

Microscopy

1. Section examined shows endometrial glands an endocervical glands. Section also shows muscle bundle arranged in interlacing pattern with round to oval plump nucleus.
2. No malignant cells and no granuloma seen.

Note : All biopsy specimen will be stored for 15 (fifteen)days, block and slides for 5(five) years only from the time of receipt at the laboratory. No request ,for any of the above ,will be entertained after the due date.

Reference

- i) Rosai and Ackerman's Surgical Pathology.
- ii) Modern Surgical Pathology.

Gulshan Yadav, MD
Consultant Pathologist