

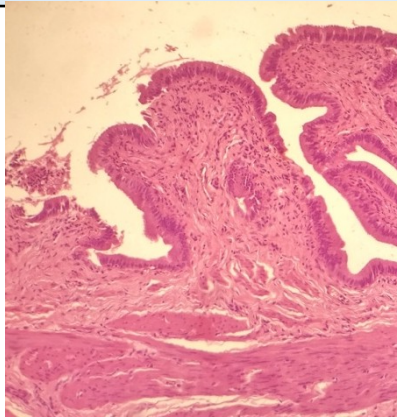
Patient Name	Miss. YASHODHA	Client Name	Civil Hospital-P, Gurgaon	Specimen Received	22-Mar-2019
Age/Sex	18/F	Client Code	MolQ1681P	Specimen Type	Tissue
Patient ID	011903220119	Ref. Doctor	DR KULDEEP	Collection Date	22-Mar-2019
Specimen ID	MOLQ/B-478/19			Report Date	26-Mar-2019

SURGICAL PATHOLOGY REPORT

GALL BLADDER.

DIAGNOSIS

CHOLECYSTITIS AND CHOLELITHIASIS



SPECIMEN

Gall Bladder.

GROSS

Received 6.2x3cm long gall bladder. Cut section shows stones.

Microscopy

- Section examined shows ulcerative mucosa and Rokitansky-Aschoff sinuses (irregularly shaped tubular structures lined by cuboidal lining epithelium with round to oval nucleus) with fibrocollagenous tissue and inflammatory cells (lymphocytes).

Note : All biopsy specimen will be stored for 15 (fifteen) days, block and slides for 5 (five) years only from the time of receipt at the laboratory. No request ,for any of the above will be entertained after the due date.

Reference

- Rosai and Ackerman's Surgical Pathology.
- Modern Surgical Pathology.

Gulshan Yadav, MD
Consultant Pathologist