

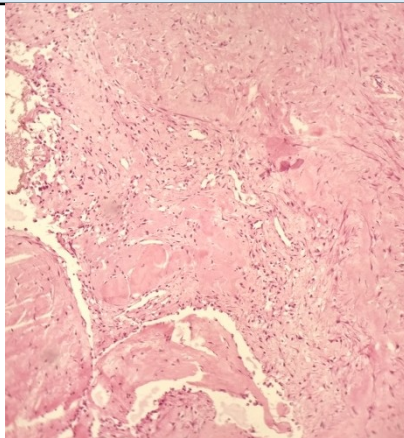
Patient Name	Mr. ADIL HUSSAIN BHAT	Client Name	Patients Care Clinical Laboratory	Specimen Received	11-Mar-2019
Age/Sex	24/M		Jammu & Kashmir	Specimen Type	Tissue
Patient ID	011903110193	Client Code	MolQ1839P	Collection Date	11-Mar-2019
Specimen ID	MOLQ/B-398-19 (A)	Ref. Doctor	NEW GEO CLI LAB	Report Date	25-Mar-2019

SURGICAL PATHOLOGY REPORT

?

DIAGNOSIS

BENIGN LESION



SPECIMEN

?

GROSS

Received 1x1cm greyish white tissue piece.

Microscopy

1. Section examined shows ducts surrounded by fibro collagenous tissue, blood vessels and mature adipose cells.
2. No granuloma and no malignant cells seen.

Note : All biopsy specimen will be stored for 15 (fifteen)days, block and slides for 5(five) years only from the time of receipt at the laboratory. No request ,for any of the above ,will be entertained after the due date.

Reference

- i) Rosai and Ackerman's Surgical Pathology.
- ii) Modern Surgical Pathology.

Gulshan Yadav, MD
Consultant Pathologist