

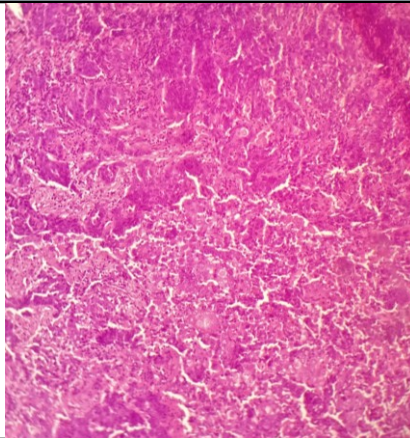
Patient Name	Mrs. MINTO	Client Name	Harshit path Lab,	Specimen Received	10-Mar-2019
Age/Sex	34/F		Gurgaon	Specimen Type	Tissue
Patient ID	011903100136	Client Code	MolQ1669P	Collection Date	10-Mar-2019
Specimen ID	MOLQ/B-395-19	Ref. Doctor		Report Date	25-Mar-2019

SURGICAL PATHOLOGY REPORT

Gall Bladder mass

DIAGNOSIS

Metastasis? Epithelial Malignancy?



SPECIMEN

Gall Bladder mass

GROSS

Received 5x3.1 cm greyish white tissue piece.

Microscopy

- Section examined shows two bits of tissues with sheets of epithelial cells with high nuclear:cytoplasmic ratio, anisonucleosis, few mitotic activities, prominent nucleoli surrounded by fibrocollagenous tissue and lymphocytes.

Note : All biopsy specimen will be stored for 15 (fifteen)days, block and slides for 5(five) years only from the time of receipt at the laboratory. No request ,for any of the above ,will be entertained after the due date.

Reference

- Rosai and Ackerman's Surgical Pathology.
- Modern Surgical Pathology.

Gulshan Yadav, MD
Consultant Pathologist