

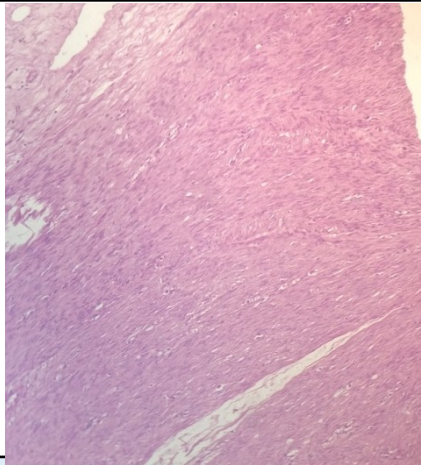
Patient Name	Mrs. PREM WATI DEVI	Client Name	Accurate Path (C), Agra	Specimen Received	20-Mar-2019
Age/Sex	42/F	Client Code	MolQ1671CM	Specimen Type	Tissue
Patient ID	011903200070	Ref. Doctor	DR. JYOTI GUPTA	Collection Date	20-Mar-2019
Specimen ID	MOLQ/B-465/19			Report Date	24-Mar-2019

SURGICAL PATHOLOGY REPORT

Uterus

DIAGNOSIS

CHORNIC CERVICITIS WITH ENDOMETRIAL POLYP



SPECIMEN

Uterus

GROSS

Received 12x5.7 cm autolysed uterus with cervix with unilateral adnexa. Ovary measuring 3x2.5 cm. Cut section shows 4x3 cm endometrial polyp.

Microscopy

Section examined shows

1. Endometrium with proliferative phase
2. Myometrium with muscle bundles
3. Cervix with mononuclear inflammatory cells
4. Poly with endometrial glands and stromal cells.

Note : All biopsy specimen will be stored for 15 (fifteen)days, block and slides for 5(five) years only from the time of receipt at the laboratory. No request ,for any of the above ,will be entertained after the due date.

Reference

- i) Rosai and Ackerman's Surgical Pathology.
- ii) Modern Surgical Pathology.

Gulshan Yadav, MD
Consultant Pathologist