

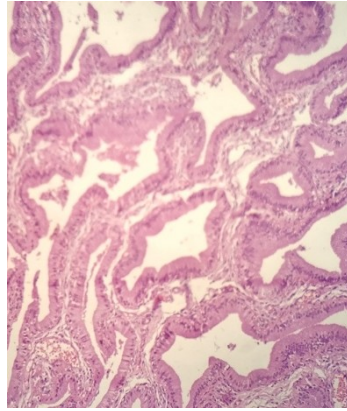
<b>Patient Name</b>	<b>Mr. GHULAM MOHD /HAJIN</b>	<b>Client Name</b>	Bandipora Collection Centre, Jammu & Kashmir	<b>Specimen Received</b>	20-Mar-2019
<b>Age/Sex</b>	70/M	<b>Client Code</b>	MolQ1929P	<b>Specimen Type</b>	Tissue
<b>Patient ID</b>	011903180436	<b>Ref. Doctor</b>	DR ISHFAQ	<b>Collection Date</b>	20-Mar-2019
<b>Specimen ID</b>	MOLQ/B-475/19			<b>Report Date</b>	24-Mar-2019

## SURGICAL PATHOLOGY REPORT

### GALL BLADDER.

#### DIAGNOSIS

#### CHOLECYSTITIS AND CHOLELITHIASIS



#### SPECIMEN

Gall Bladder.

#### GROSS

Received 6.2x2.3 cm long gall bladder. Cut section shows tiny stones.

#### Microscopy

- Section examined shows ulcerative mucosa and Rokitansky-Aschoff sinuses (irregularly shaped tubular structures lined by cuboidal lining epithelium with round to oval nucleus) with fibro collagenous tissue and inflammatory cells (lymphocytes).

**Note :** All biopsy specimen will be stored for 15 (fifteen) days, block and slides for 5 (five) years only from the time of receipt at the laboratory. No request ,for any of the above will be entertained after the due date.

#### Reference

- Rosai and Ackerman's Surgical Pathology.
- Modern Surgical Pathology.

**Gulshan Yadav, MD  
Consultant Pathologist**