

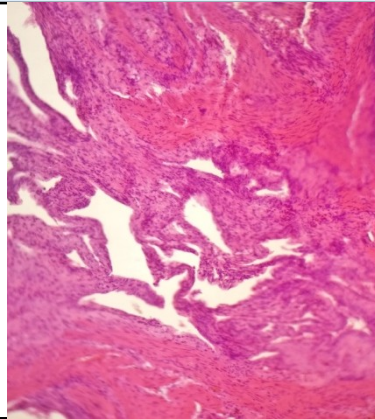
Patient Name	Mrs. LAXMI 26897	Client Name	Pushpanjali Hospital ,	Specimen Received	18-Mar-2019
Age/Sex	59/F		Rewari	Specimen Type	Tissue
Patient ID	011903180310	Client Code	MolQ1789CM	Collection Date	18-Mar-2019
Specimen ID	MOLQ/B-460/19	Ref. Doctor	DR.KULDEEP	Report Date	20-Mar-2019

SURGICAL PATHOLOGY REPORT

GALL BLADDER.

DIAGNOSIS

CHOLECYSTITIS



SPECIMEN

Gall Bladder.

GROSS

Received 4.5x4.2 cm long gall bladder without stones..

Microscopy

1. Section examined shows ulcerative mucosa and Rokitansky-Aschoff sinuses (irregularly shaped tubular structures lined by cuboidal lining epithelium with round to oval nucleus) with fibrocollagenous tissue and inflammatory cells (lymphocytes).

Note : All biopsy specimen will be stored for 15 (fifteen) days, block and slides for 5 (five) years only from the time of receipt at the laboratory. No request ,for any of the above will be entertained after the due date.

Reference

- i) Rosai and Ackerman's Surgical Pathology.
- ii) Modern Surgical Pathology.

Gulshan Yadav, MD
Consultant Pathologist