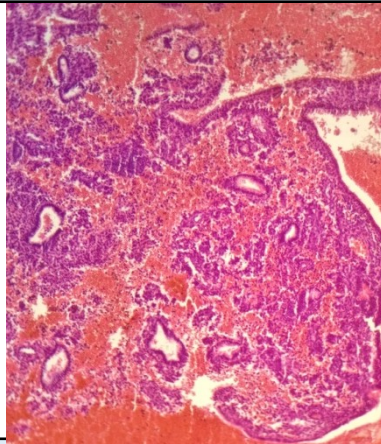


Patient Name	Ms. SANDEEP KAUR	Client Name	Malhotra Diagnostics,	Specimen Received	18-Feb-2019
Age/Sex	40/F		Gurgaon	Specimen Type	Tissue
Patient ID	011903180213	Client Code	MolQ1475P	Collection Date	18-Feb-2019
Specimen ID	MOLQ/B-461/19	Ref. Doctor		Report Date	20-Feb-2019

SURGICAL PATHOLOGY REPORT

Endocervical Biopsy

PROLIFERATIVE PHASE



SPECIMEN

Endocervical Biopsy

GROSS

Received multiple greyish white tissue piece.

Microscopy

1. Section examined shows small endometrial glands having columnar lining epithelium with small round to oval nucleus. Stroma shows mononuclear cells and RBCs.
2. No granuloma and no malignant cells seen.

Note : All biopsy specimen will be stored for 15 (fifteen) days, block and slides for 5 (five) years only from the time of receipt at the laboratory. No request for any of the above, will be entertained after the due date.

Reference

- i) Rosai and Ackerman's Surgical Pathology.
- ii) Modern Surgical Pathology.

Gulshan Yadav, MD
Consultant Pathologist