

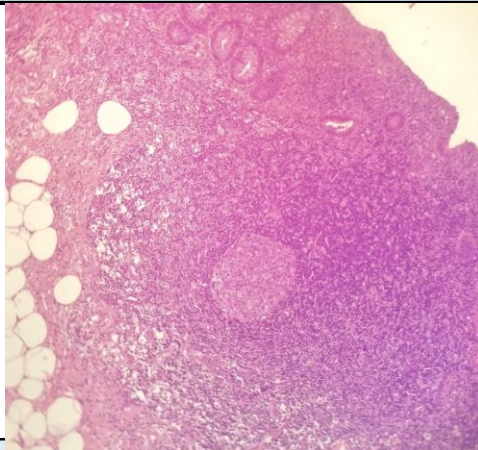
Patient Name	Miss. MANYA GERA	Client Name	Lifeaid Wellness Centre	Specimen Received	17/03/2019
Age/Sex	13 Years/Female	Client Code	MolQ1476CM	Specimen Type	Tissue
Patient ID	011903170039	Ref. Doctor		Collection Date	17/03/2018
Specimen ID	MOLQ/B-450/19			Report Date	19/03/2018

SURGICAL PATHOLOGY REPORT

APPENDIX.

DIAGNOSIS

ACUTE APPENDICITIS



SPECIMEN

Appendix.

GROSS

Received 4.6x2.3cm appendix cut section shows fecolith.

Microscopy

- Section examined shows lymphoid follicles with ulcerative mucosa. Deeper tissue shows inflammatory cells (polymorphs, lymphocytes and few histiocytes).

Note : All biopsy specimen will be stored for 15 (fifteen) days, block and slides for 5 (five) years only from the time of receipt at the laboratory. No request, for any of the above, will be entertained after the due date.

Reference

- Rosai and Ackerman's Surgical Pathology.
- Modern Surgical Pathology.

Gulshan Yadav, MD
Consultant Pathologist