

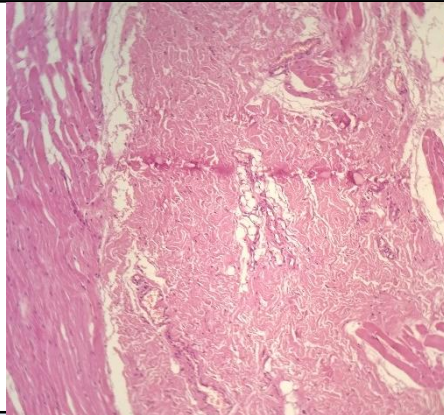
Patient Name	Mr. SATPAL	Client Name	Galaxy Hospital, Palwal	Specimen Received	16/03/2019
Age/Sex	32 Years/Male	Client Code	MolQ1890P	Specimen Type	Tissue
Patient ID	011903160318	Ref. Doctor		Collection Date	16/03/2019
Specimen ID	MOLQ/B-445/19			Report Date	19/03/2019

SURGICAL PATHOLOGY REPORT

Dermoid cyst

DIAGNOSIS

Dermoid cyst



SPECIMEN

Dermoid cyst

GROSS

Received 1x1cm greyish white tissue piece.

Microscopy

- Section examined shows Squamous mucosal lining epithelium with round to oval nucleus stromal cells, blood vessels, fibro collagenous tissue no granuloma and no malignant cells seen.

Note : All biopsy specimen will be stored for 15 (fifteen)days, block and slides for 5(five) years only from the time of receipt at the laboratory. No request ,for any of the above ,will be entertained after the due date.

Reference

- Rosai and Ackerman's Surgical Pathology.
- Modern Surgical Pathology.

Gulshan Yadav, MD
Consultant Pathologist