

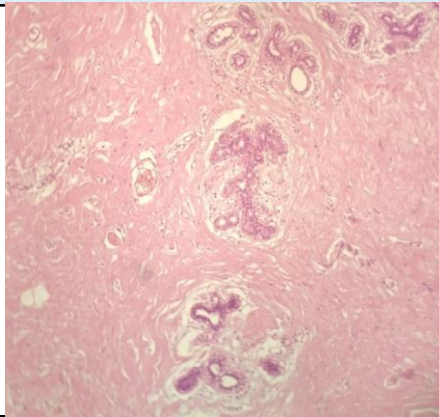
<b>Patient Name</b>	<b>Miss. SHABNAM</b>	<b>Client Name</b>	Galaxy Hospital, Palwal	<b>Specimen Received</b>	16/03/2019
<b>Age/Sex</b>	19 Years/Female	<b>Client Code</b>	MolQ1890P	<b>Specimen Type</b>	Tissue
<b>Patient ID</b>	011903160317	<b>Ref. Doctor</b>		<b>Collection Date</b>	16/03/2019
<b>Specimen ID</b>	MOLQ/B-444/19			<b>Report Date</b>	19/03/2019

## SURGICAL PATHOLOGY REPORT

### Left breast

#### DIAGNOSIS

**Fibroadenoma**



#### SPECIMEN

Left breast

#### GROSS

Received 3.9x2.8cm greyish white tissue piece with attached fat tissue.

#### Microscopy

1. Section examined shows cystically dilated ducts with cuboidal epithelium with small round nucleus surrounded by fibro collagenous tissue.
2. No granuloma seen.
3. No malignant cells seen.

**Note :** All biopsy specimen will be stored for 15 (fifteen)days, block and slides for 5(five) years only from the time of receipt at the laboratory. No request ,for any of the above ,will be entertained after the due date.

#### Reference

- i) Rosai and Ackerman's Surgical Pathology.
- ii) Modern Surgical Pathology.

**Gulshan Yadav, MD  
Consultant Pathologist**