

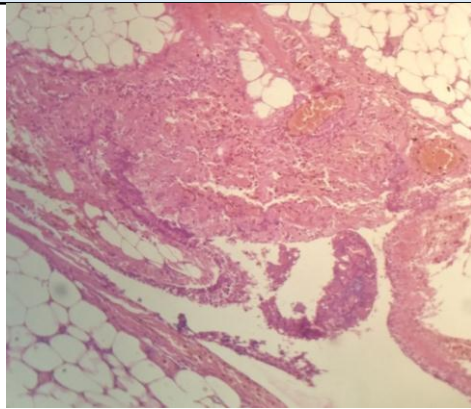
<b>Patient Name</b>	<b>Mrs. NEERA DEVI</b>	<b>Client Name</b>	Civil Hospital-P	<b>Specimen Received</b>	16/03/2019
<b>Age/Sex</b>	35 Years/Female	<b>Client Code</b>	MolQ1681P	<b>Specimen Type</b>	Tissue
<b>Patient ID</b>	011903160284	<b>Ref. Doctor</b>	DR.VIVEK	<b>Collection Date</b>	16/03/2019
<b>Specimen ID</b>	MOLQ/B-443/19			<b>Report Date</b>	19/03/2019

## SURGICAL PATHOLOGY REPORT

### Fibroadenoma left breast.

#### DIAGNOSIS

**Fibroadenoma**



#### SPECIMEN

Fibroadenoma left breast.

#### GROSS

Received 4.5x3.4cm greyish white tissue piece well an capsulated.

#### Microscopy

1. Section examined shows cystically dilated ducts with cuboidal epithelium with small round nucleus surrounded by fibro collagenous tissue.

No granuloma seen.

2. No malignant cells seen.

**Note :** All biopsy specimen will be stored for 15 (fifteen)days, block and slides for 5(five) years only from the time of receipt at the laboratory. No request ,for any of the above ,will be entertained after the due date.

#### Reference

- i) Rosai and Ackerman's Surgical Pathology.
- ii) Modern Surgical Pathology.

**Gulshan Yadav, MD**  
**Consultant Pathologist**