

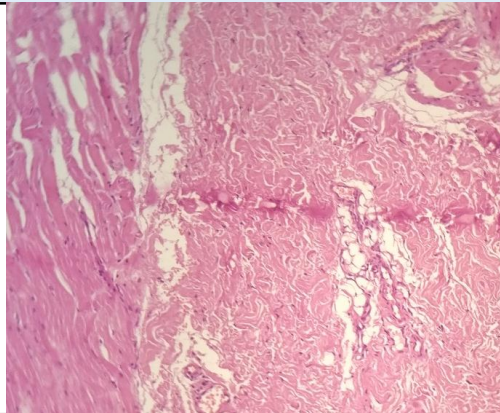
| | | | | | |
|---------------------|----------------------|--------------------|------------------------------|--------------------------|------------|
| Patient Name | Mr. BILQUEESA | Client Name | New Unique Diagnostic Center | Specimen Received | 16/03/2019 |
| Age/Sex | .Years/male | | Jammu & Kashmir | Specimen Type | Tissue |
| Patient ID | 011903160020 | Client Code | MolQ1833P | Collection Date | 16/03/2019 |
| Specimen ID | MOLQ/B-438/19 | Ref. Doctor | BILQUEESA BEGUM(DAB) | Report Date | 19/03/2019 |

SURGICAL PATHOLOGY REPORT

GALL BLADDER.

DIAGNOSIS

CHOLECYSTITIS WITH CHOLELITHIASIS



SPECIMEN

Gall Bladder.

GROSS

Received 6x2.1cm long gall bladder cut section shows no stones.

Microscopy

1. Section examined shows ulcerative mucosa and Rokitansky-Aschoff sinus (irregularly shaped tubular structures lined by cuboidal lining epithelium with round to oval nucleus) with fibro collagenous tissue and inflammatory cells (lymphocytes).

Note : All biopsy specimen will be stored for 15 (fifteen) days, block and slides for 5 (five) years only from the time of receipt at the laboratory. No request, for any of the above, will be entertained after the due date.

Reference

- i) Rosai and Ackerman's Surgical Pathology.
- ii) Modern Surgical Pathology.

**Gulshan Yadav, MD
Consultant Pathologist**