

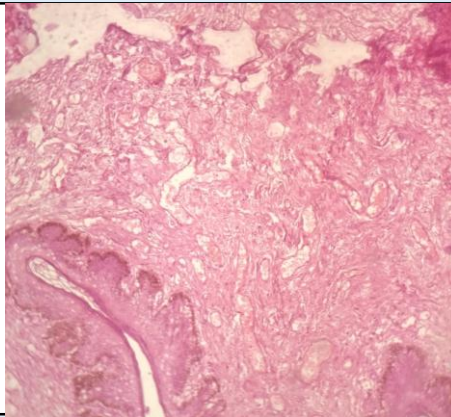
Patient Name	Mr. ALTAF AHMAD	Client Name	New Unique Diagnostic Center,	Specimen Received	14/03/2019
Age/Sex	45 Years/Male		Jammu & Kashmir	Specimen Type	Tissue
Patient ID	011903130446	Client Code	MolQ1833P	Collection Date	14/03/2019
Specimen ID	MOLQ/B-430/19	Ref. Doctor	AFTAB LAB HAJIN	Report Date	19/03/2019

SURGICAL PATHOLOGY REPORT

Rectal polyp

DIAGNOSIS

Skin tag



SPECIMEN

Rectal polyp

GROSS

Received 1x1.5cm greyish white tissue piece.

Microscopy

- Section examined shows Squamous lining epithelium with small round nucleus.
Deeper tissue shows glands, fibro collagenous tissue, blood vessels.
No granuloma and no malignant cells seen.

Note : All biopsy specimen will be stored for 15 (fifteen)days, block and slides for 5(five) years only from the time of receipt at the laboratory. No request ,for any of the above ,will be entertained after the due date.

Reference

- Rosai and Ackerman's Surgical Pathology.
- Modern Surgical Pathology.

Gulshan Yadav, MD
Consultant Pathologist