

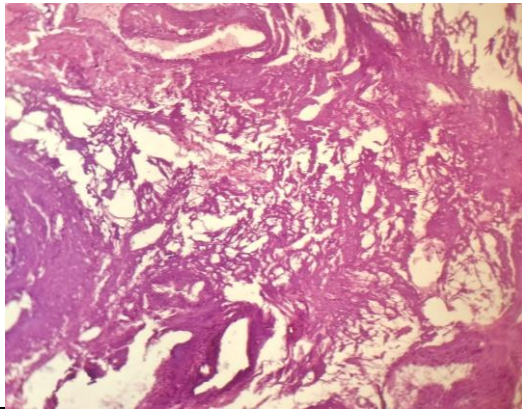
Patient Name	DHARMBEER	Client Name	Pushpanjali Hospital (Rewari)	Specimen Received	15/03/2019
Age/Sex	25 YRS/M	Client Code	MolQ1789CM	Specimen Type	Tissue
Patient ID	011903150337	Ref. Doctor	DR. KULDEEP	Collection Date	15/03/2019
Specimen ID	MOLQ/B-435/19			Report Date	18/03/2019

SURGICAL PATHOLOGY REPORT

Hemorrhoids

DIAGNOSIS

HEMORROIDS



SPECIMEN

Hemorrhoids

GROSS

Received autolyzed 2x2 cm greyish white tissue piece.

Microscopy

- Section examined shows submucosal glands, fibro collagenous tissue with blood vessels. No granuloma and no malignant cells seen.

Note : All biopsy specimen will be stored for 15 (fifteen)days, block and slides for 5(five) years only from the time of receipt at the laboratory. No request ,for any of the above ,will be entertained after the due date.

Reference

- Rosai and Ackerman's Surgical Pathology.
- Modern Surgical Pathology.

Gulshan Yadav, MD
Consultant Pathologist