

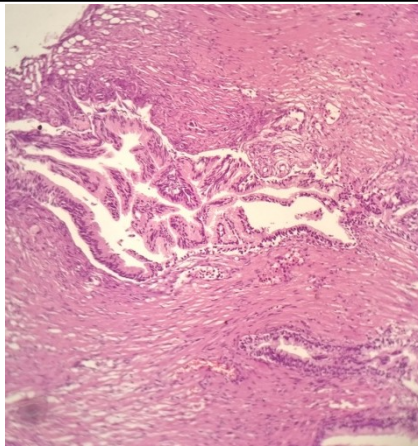
<b>Patient Name</b>	Mr. SHYAM BHIYARI	<b>Client Name</b>	Pushpanjali Hospital	<b>Specimen Received</b>	13-Mar-2019
<b>Age/Sex</b>	70/M		(Rewari)	<b>Specimen Type</b>	Tissue
<b>Patient ID</b>	011903130464	<b>Client Code</b>	MolQ1839P	<b>Collection Date</b>	13-Mar-2019
<b>Specimen ID</b>	MOLQ/B-419/19	<b>Ref. Doc</b>	DR. Kamal	<b>Report Date</b>	16-Mar-2019

## SURGICAL PATHOLOGY REPORT

### TURP

#### DIAGNOSIS

**BENIGN PROSTATIC HYPERPLASIA.**



#### SPECIMEN

TURP

#### GROSS

Received multiple greyish white tissue piece 5x7 cm in aggregate.

#### Microscopy

- Section examined shows bilayered prostatic glands with columnar lining epithelium and with small round to oval nucleus surrounded by large number of fibrocollagenous tissue and mononuclear inflammatory cell.

**Note :** All biopsy specimen will be stored for 15 (fifteen) days, block and slides for 5 (five) years only from the time of receipt at the laboratory. No request, for any of the above, will be entertained after the due date.

#### Reference

- Rosai and Ackerman's Surgical Pathology.
- Modern Surgical Pathology.

**Gulshan Yadav, MD**  
Consultant Pathologist