

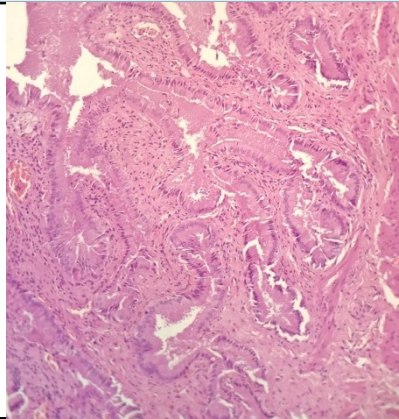
| | | | | | |
|---------------------|---------------|--------------------|------------------------------|--------------------------|-------------|
| Patient Name | Mrs. PREETI | Client Name | Civil Hospital-P, Gurgaon | Specimen Received | 13-Mar-2019 |
| Age/Sex | 27/F | Client Code | MolQ1681P | Specimen Type | Tissue |
| Patient ID | 011903130230 | Ref. Doctor | | Collection Date | 13-Mar-2019 |
| Specimen ID | MOLQ/B-416/19 | | | Report Date | 16-Mar-2019 |

SURGICAL PATHOLOGY REPORT

GALL BLADDER.

DIAGNOSIS

CHOLECYSTITIS AND CHOLELITHIASIS.



SPECIMEN

Gall Bladder.

GROSS

Received 6.5x2.8cm long gall bladder. Cut section shows stones.

Microscopy

- Section examined shows ulcerative mucosa and Rokitansky-Aschoff sinuses (irregularly shaped tubular structures lined by cuboidal lining epithelium with round to oval nucleus) with fibrocollagenous tissue and inflammatory cells (lymphocytes).

Note : All biopsy specimen will be stored for 15 (fifteen) days, block and slides for 5 (five) years only from the time of receipt at the laboratory. No request ,for any of the above will be entertained after the due date.

Reference

- Rosai and Ackerman's Surgical Pathology.
- Modern Surgical Pathology.

**Gulshan Yadav, MD
Consultant Pathologist**