

Patient Name	ZAINA W.O GH RASOOL	Client Name	Patients Care Clinical Laboratory	Specimen Received	11/03/2019
Age/Sex	70/F		Jammu & Kashmir	Specimen Type	Tissue
Patient ID	011903110194	Client Code	MolQ1681P	Collection Date	11/03/2019
Specimen ID	MOLQ/B-399/19	Ref. Doctor	S Z CLI LAB (D H ANG)	Report Date	16/03/2019

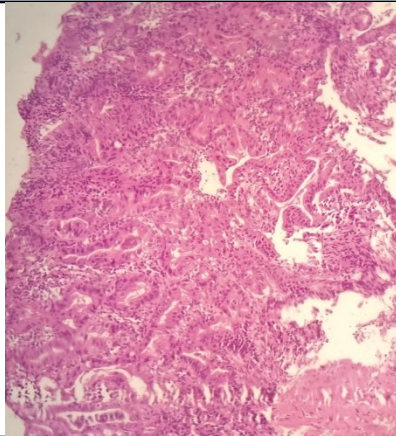
SURGICAL PATHOLOGY REPORT

Endoscopic biopsy

DIAGNOSIS

DYSPLASTIC EPITHELIUM.

Advised: Immunohistochemical study for further diagnosis.



SPECIMEN

Endoscopic biopsy

GROSS

Received multiple tiny greyish white tissue piece.

Microscopy

1. Section examined shows mucosal lining epithelium with anisonucleosis hyperchromatism, altered nuclear and cytoplasmic ratio and mitotic figures.
2. Deeper tissue shows fibro collagenous tissue, inflammatory infiltrate.

Note : All biopsy specimen will be stored for 15 (fifteen)days, block and slides for 5(five) years only from the time of receipt at the laboratory. No request ,for any of the above ,will be entertained after the due date.

Reference

- i) Rosai and Ackerman's Surgical Pathology.
- ii) Modern Surgical Pathology. *Report generated at MolQ Laboratory, Gurgaon*

Gulshan Yadav, MD
Consultant Pathologist