

<b>Patient Name</b>	Mr. AKBAR	<b>Client Name</b>	Nisha Diagnostic Centre	<b>Specimen Received</b>	09/03/2019
<b>Age/Sex</b>	25/M	<b>Client Code</b>	MolQ1588P	<b>Specimen Type</b>	Tissue
<b>Patient ID</b>	011903090211	<b>Ref. Doctor</b>		<b>Collection Date</b>	09/03/2019
<b>Specimen ID</b>	MOLQ/B-388/19			<b>Report Date</b>	17/03/2019

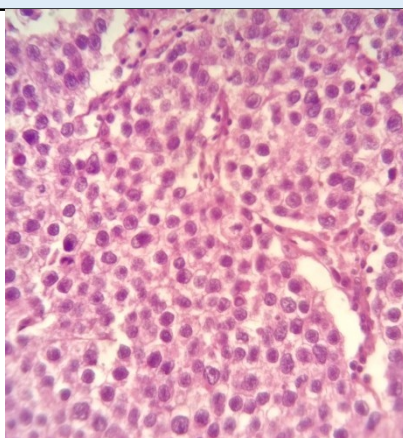
## SURGICAL PATHOLOGY REPORT

Testes (side unidentified)

### IMPRESSION

### DIAGNOSIS

**SEMINOMA**



### SPECIMEN

Testes

### GROSS

Received 7x4cm greyish white tissue piece with 3x2cm testes with epididymis.

### Microscopy

Section from testes, epididymis and surrounding tissue shows sheets of tumor cell, uniformly and variable in size (admixed with medium sized cells (predominantly), few bizarre giant cells and small lymphocytes like cells) having prominent nucleoli and filamentous appearance.

Cytoplasm is dense eosinophilic.

Presence of lymphocytic infiltration within the tumor mass. Mitotic activities are present.

**Note :** All biopsy specimen will be stored for 15 (fifteen) days, block and slides for 5 (five) years only from the time of receipt at the laboratory. No request, for any of the above, will be entertained after the due date.

### Reference

- i) Rosai and Ackerman's Surgical Pathology.
- ii) Modern Surgical Pathology. Report generated at MolQ Laboratory, Gurgaon

**Gulshan Yadav, MD**  
Consultant Pathologist