

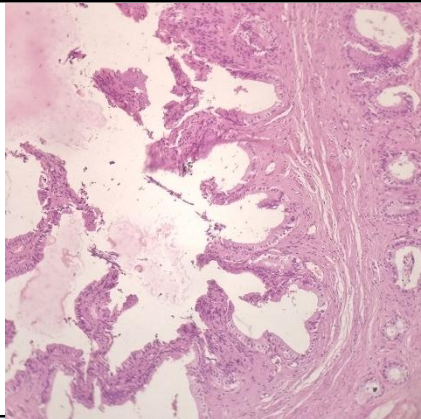
<b>Patient Name</b>	<b>Mrs. NEELAM-23467</b>	<b>Client Name</b>	Pushpanjali Hospital	<b>Specimen Received</b>	11-Mar-2019
<b>Age/Sex</b>	34/F		(Rewari)	<b>Specimen Type</b>	Tissue
<b>Patient ID</b>	011903110462	<b>Client Code</b>	MoIQ1789CM	<b>Collection Date</b>	11-Mar-2019
<b>Specimen ID</b>	MOLQ/B-406/19	<b>Ref. Doc</b>	DR KULDEEP	<b>Report Date</b>	15-Mar-2019

## SURGICAL PATHOLOGY REPORT

### Gall bladder

#### DIAGNOSIS

**CHOLECYSTITIS AND CHOLELITHIASIS.**



#### **SPECIMEN**

Gall bladder

#### **GROSS**

Received 5.9x2.7 cm long gall bladder Cut section shows tiny stones.

#### **Microscopy**

Section examined shows ulcerative mucosa and Rokitansky Aschoff sinus (irregularly shaped tubular structures lined by cuboidal lining epithelium with round to oval nucleus) with fibro collagenous tissue and inflammatory cells (lymphocytes).

**Note :** All biopsy specimen will be stored for 15 (fifteen) days, block and slides for 5 (five) years only from the time of receipt at the laboratory. No request ,for any of the above will be entertained after the due date.

#### **Reference**

- i) Rosai and Ackerman's Surgical Pathology.
- ii) Modern Surgical Pathology.

**Gulshan Yadav, MD  
Consultant Pathologist**