

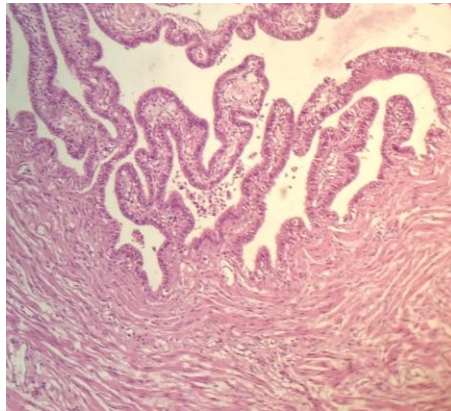
<b>Patient Name</b>	Mrs. FEHMEEDA	<b>Client Name</b>	Patients Care Clinical Laboratory,	<b>Specimen Received</b>	11-Mar-2019
<b>Age/Sex</b>	33/F		Jammu & Kashmir	<b>Specimen Type</b>	Tissue
<b>Patient ID</b>	0119031100199	<b>Client Code</b>	MolQ1839P	<b>Collection Date</b>	11-Mar-2019
<b>Specimen ID</b>	MOLQ/B-401/19	<b>Ref. Doc</b>	NEW GEO CLI LAB (OPD)	<b>Report Date</b>	15-Mar-2019

## SURGICAL PATHOLOGY REPORT

### Gall bladder

#### DIAGNOSIS

**CHOLECYSTITIS AND CHOLELITHIASIS.**



#### SPECIMEN

Gall bladder

#### GROSS

Received autolyzed 9x2.8cm long gallbladder with stones.

#### Microscopy

Section examined shows autolyzed ulcerative mucosa and Rokitansky-Aschoff sinus (irregularly shaped tubular structures lined by cuboidal lining epithelium with round to oval nucleus) with fibro collagenous tissue and inflammatory cells (lymphocytes).

**Note :** All biopsy specimen will be stored for 15 (fifteen) days, block and slides for 5 (five) years only from the time of receipt at the laboratory. No request ,for any of the above will be entertained after the due date.

#### Reference

- i) Rosai and Ackerman's Surgical Pathology.
- ii) Modern Surgical Pathology.

**Gulshan Yadav, MD**  
Consultant Pathologist