

| | | | | | |
|---------------------|---------------|--------------------|-------------------------------|--------------------------|------------|
| Patient Name | Mr. SURENDER | Client Name | Pushpanjali Hospital (Rewari) | Specimen Received | 10/03/2019 |
| Age/Sex | 74 Years/male | Client Code | | Specimen Type | Tissue |
| Patient ID | 011903100281 | Ref. Doc | | Collection Date | 10/03/2019 |
| Specimen ID | MOLQ/B-396/19 | | | Report Date | 15/03/2019 |

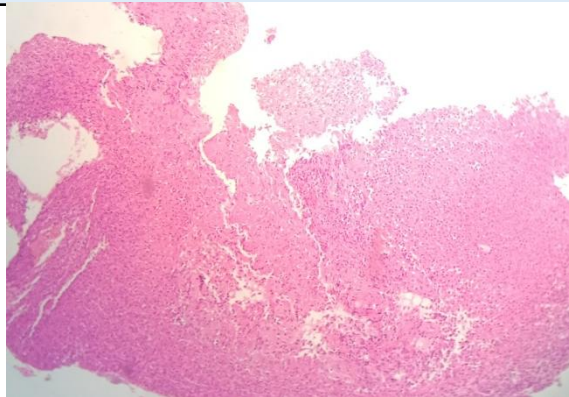
SURGICAL PATHOLOGY REPORT

Endoscopic biopsy

DIAGNOSIS

Non specific Inflammation with Reactive Atypia of the Glands.

Kindly Co-relate clinically with radiologically findings .



SPECIMEN

Endoscopic biopsy

GROSS

Received very tiny greyish white tissue piece.

Microscopy

Section examined shows large number of inflammatory cells (polymorphs, lymphocyte) and blood vessels.

Section also shows glands with round to oval nucleus with mild atypia with anisonucleosis. No granuloma and no malignant cells seen.

Note : All biopsy specimen will be stored for 15 (fifteen) days, block and slides for 5 (five) years only from the time of receipt at the laboratory. No request ,for any of the above will be entertained after the due date.

Reference

- i) Rosai and Ackerman's Surgical Pathology.
- ii) Modern Surgical Pathology.

**Gulshan Yadav, MD
Consultant Pathologist**