

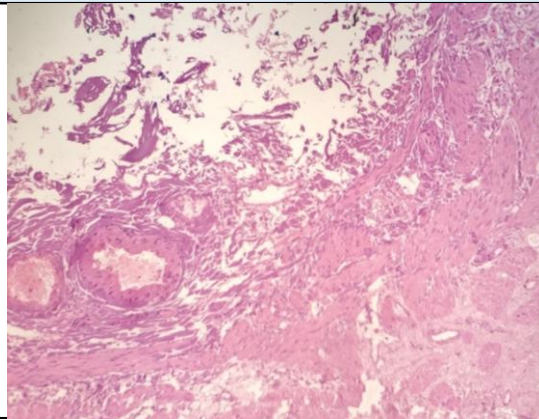
<b>Patient Name</b>	<b>Mrs. HAMIDA (DANTER)</b>	<b>Client Name</b>	Patients Care Clinical Laboratory,	<b>Specimen Received</b>	09-Mar-2019
<b>Age/Sex</b>	45/F		Jammu & Kashmir	<b>Specimen Type</b>	Tissue
<b>Patient ID</b>	011903090142	<b>Client Code</b>	MolQ1850P	<b>Collection Date</b>	09-Mar-2019
<b>Specimen ID</b>	MOLQ/B-394/19	<b>Ref. Doc</b>	PATIENTS CARE CLI LAB	<b>Report Date</b>	14-Mar-2019

**SURGICAL PATHOLOGY REPORT**

**GALL BLADDER.**

**DIAGNOSIS**

**CHOLECYSTITIS WITH CHOLELITHIASIS**



**SPECIMEN**

Gall Bladder.

**GROSS**

Received 6.2x2.8cm long gall bladder with stones.

**Microscopy**

1. Section examined shows ulcerative mucosa and rokitansky aschoff sinus (irregularly shaped tubular structures lined by cuboidal lining epithelium with round to oval nucleus) with fibro collagenous tissue and inflammatory cells (lymphocytes).

**Note :** All biopsy specimen will be stored for 15 (fifteen) days, block and slides for 5 (five) years only from the time of receipt at the laboratory. No request ,for any of the above will be entertained after the due date.

**Reference**

- i) Rosai and Ackerman's Surgical Pathology.
- ii) Modern Surgical Pathology.

**Gulshan Yadav, MD  
Consultant Pathologist**