

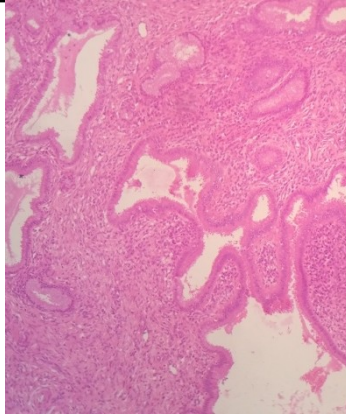
Patient Name	Mrs. MURTI DEVI	Client Name	Life Care Path Lab,	Specimen Received	09-Mar-2019
Age/Sex	53/F		Tauru	Specimen Type	Tissue
Patient ID	011903090204	Client Code	MolQ1518P	Collection Date	09-Mar-2019
Specimen ID	MOLQ/B-387/19	Ref. Doctor		Report Date	13-Mar-2019

SURGICAL PATHOLOGY REPORT

GALL BLADDER.

DIAGNOSIS

CHOLECYSTITIS AND CHOLELITHIASIS.



SPECIMEN

Gall Bladder.

GROSS

Received 6.8x2.1cm long gall bladder. Cut section shows stones.

Microscopy

- Section examined shows ulcerative mucosa and Rokitansky-Aschoff sinuses (irregularly shaped tubular structures lined by cuboidal lining epithelium with round to oval nucleus) with fibrocollagenous tissue and inflammatory cells (lymphocytes).

Note : All biopsy specimen will be stored for 15 (fifteen) days, block and slides for 5 (five) years only from the time of receipt at the laboratory. No request ,for any of the above will be entertained after the due date.

Reference

- Rosai and Ackerman's Surgical Pathology.
- Modern Surgical Pathology.

**Gulshan Yadav, MD
Consultant Pathologist**