

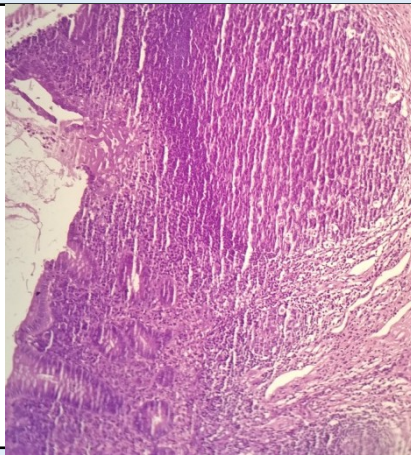
Patient Name	Mr. CHAVNATH -26562	Client Name	Pushpanjali Hospital	Specimen Received	08/03/2019
Age/Sex	36 YRS/M		(Rewari)	Specimen Type	Tissue
Patient ID	011903080437	Client Code	MolQ1789CM	Collection Date	08/03/2019
Specimen ID	MOLQ/B-381/19 (1)	Ref. Doctor	Dr. KULDEEP	Report Date	13/03/2019

SURGICAL PATHOLOGY REPORT

Appendix

DIAGNOSIS

ACUTE APPENDICITIS



SPECIMEN

Appendix

GROSS

Received 5x1.8cm long appendix cut section shows fecolith.

Microscopy

- Section examined shows lymphoid follicles with ulcerative mucosa. Deeper tissue shows inflammatory cells (polymorphs, lymphocytes and few histiocytes).

Note : All biopsy specimen will be stored for 15 (fifteen)days, block and slides for 5(five) years only from the time of receipt at the laboratory. No request ,for any of the above ,will be entertained after the due date.

Reference

- Rosai and Ackerman's Surgical Pathology.
- Modern Surgical Pathology.

Gulshan Yadav, MD
Consultant Pathologist