

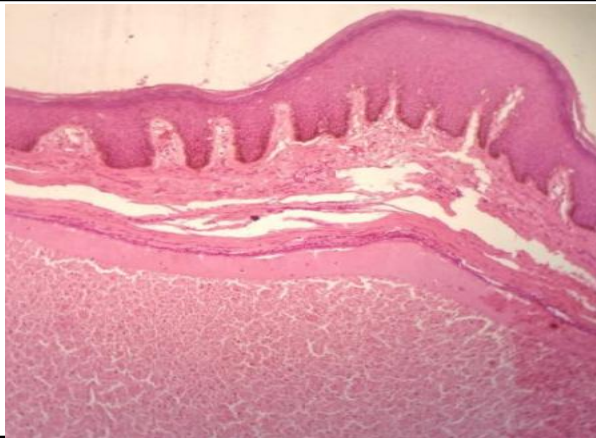
<b>Patient Name</b>	Mrs. VIMAL	<b>Client Name</b>	Civil Hospital Sec-10	<b>Specimen Received</b>	07/03/2019
<b>Age/Sex</b>	47 YRS/F			<b>Specimen Type</b>	Tissue
<b>Patient ID</b>	011903070256			<b>Collection Date</b>	07/03/2019
<b>Specimen ID</b>	MOLQ/B-374/19			<b>Report Date</b>	11/03/2019

## SURGICAL PATHOLOGY REPORT

Labial cyst

### DIAGNOSIS

**Benign cystic lesion**



#### SPECIMEN

Labial cyst

#### GROSS

Received 3x3.5cm greyish white tissue piece cut section shows chocolate material.

#### Microscopy

- Section examined shows Squamous lining epithelium having round to oval nucleus with cystic lining with cuboidal epithelium and small round nucleus and mucoid material with RBCs and inflammatory cells.  
No granuloma and no malignant cells seen.

**Note :** All biopsy specimen will be stored for 15 (fifteen)days, block and slides for 5(five) years only from the time of receipt at the laboratory. No request ,for any of the above ,will be entertained after the due date.

#### Reference

- Rosai and Ackerman's Surgical Pathology.
- Modern Surgical Pathology. *Report generated at MolQ Laboratory, Gurgaon*

**Gulshan Yadav, MD**  
Consultant Pathologist