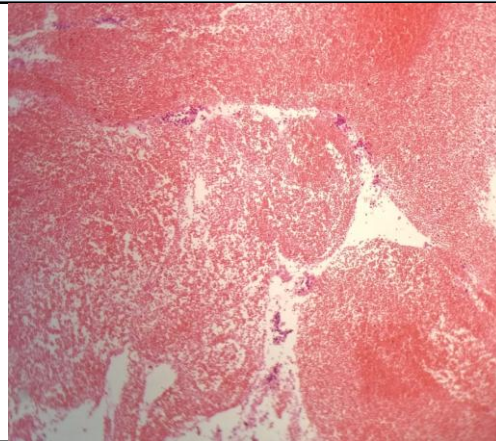


Patient Name	Mrs. VINEETA	Client Name	Accurate Path (C),	Specimen Received	07/03/2019
Age/Sex	38 Years/Female		Agra	Specimen Type	Tissue
Patient ID	011903070001	Client Code	MolQ1671CM	Collection Date	07/03/2019
Specimen ID	MOLQ/B-368/19	Ref. Doctor	Dr.Jyoti Gupta	Report Date	11/03/2019

SURGICAL PATHOLOGY REPORT

ENDOMETRIUM

Kindly Co-relate clinically



SPECIMEN

Endometrium

GROSS

Received multiple greyish white tissue piece.

Microscopy

1. Paucicellular section examined shows large number of RBCs with occasional stromal cells with occasional broken endometrial glands.

Note : All biopsy specimen will be stored for 15 (fifteen) days, block and slides for 5 (five) years only from the time of receipt at the laboratory. No request for any of the above, will be entertained after the due date.

Reference

- i) Rosai and Ackerman's Surgical Pathology.
- ii) Modern Surgical Pathology.

**Gulshan Yadav, MD
Consultant Pathologist**