

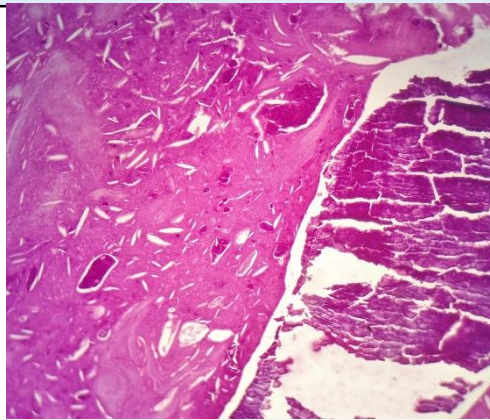
Patient Name	Mrs. MAHENDRI	Client Name	Shri Balaji Multispeciality Hospital-	Specimen Received	08/03/2019
Age/Sex	66Years/Female		Gurgaon	Specimen Type	Tissue
Patient ID	011903080117	Client Code	MolQ1269CM	Collection Date	08/03/2019
Specimen ID	MOLQ/B-379/19			Report Date	11/03/2019

SURGICAL PATHOLOGY REPORT

Infective epidermal cyst (Scalp).

DIAGNOSIS

Epidermal cyst with calcification scalp.



SPECIMEN

Infective epidermal cyst (Scalp).

GROSS

Received 2x2 greyish white tissue piece with skin cut section shows necrotic material.

Microscopy

1. Section examined shows Squamous lining epithelium with keratin flakes with calcified tissue, blood vessels.
2. No Granuloma and no malignant cells seen.

Note : All biopsy specimen will be stored for 15 (fifteen) days, block and slides for 5 (five) years only from the time of receipt at the laboratory. No request ,for any of the above will be entertained after the due date.

Reference

- i) Rosai and Ackerman's Surgical Pathology.
- ii) Modern Surgical Pathology.

Gulshan Yadav, MD
Consultant Pathologist