

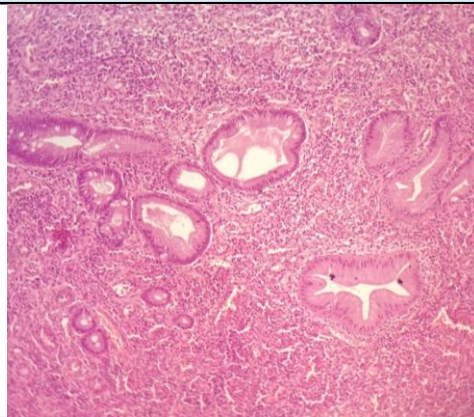
Patient Name	Master. AAZIM AIJAZ	Client Name	Bandipora Collection Centre	Specimen Received	06/03/2019
Age/Sex	04 YRS/M		(Jammu & Kashmir)	Specimen Type	Tissue
Patient ID	011903050374			Collection Date	06/03/2019
Specimen ID	MOLQ/B-362/19	Ref. Doctor	DR ISHFAQ	Report Date	12/03/2019

SURGICAL PATHOLOGY REPORT

Rectal polyp

DIAGNOSIS

Inflammatory polyp



SPECIMEN

Rectal polyp

GROSS

Received 1x1cm greyish white tissue piece.

Microscopy

- Section examined shows submucosal glands having columnar lining epithelium with round to oval nucleus with large number of inflammatory cells (lymphocytes, polymorphs, plasma cells and eosinophil) and blood vessels.
- No granuloma and no malignant cells seen.

Note : All biopsy specimen will be stored for 15 (fifteen) days, block and slides for 5 (five) years only from the time of receipt at the laboratory. No request ,for any of the above will be entertained after the due date.

Reference

- Rosai and Ackerman's Surgical Pathology.
- Modern Surgical Pathology.

Gulshan Yadav, MD
Consultant Pathologist