

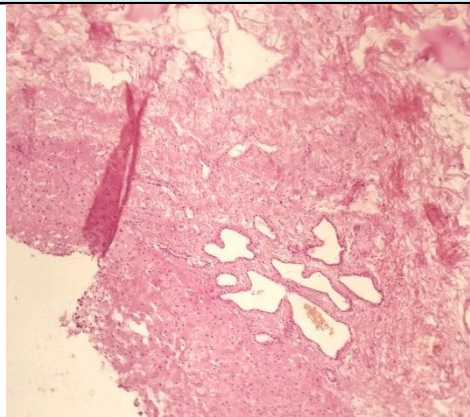
Patient Name	Mr. MUSHTAQ	Client Name	Bandipora Collection Centre	Specimen Received	06/03/2019
Age/Sex	48 YRS/M		(Jammu & Kashmir)	Specimen Type	Tissue
Patient ID	011903050373			Collection Date	06/03/2019
Specimen ID	MOLQ/B-363/19	Ref. Doctor	DR ISHFAQ	Report Date	12/03/2019

SURGICAL PATHOLOGY REPORT

GALL BLADDER.

DIAGNOSIS

CHOLECYSTITIS AND CHOLELITHIASIS.



SPECIMEN

Gall Bladder.

GROSS

Received 5x2.9cm long gall bladder cut section shows stones.

Microscopy

- Section examined shows ulcerative mucosa and Rokitansky Aschoff sinus (irregularly shaped tubular structures lined by cuboidal lining epithelium with round to oval nucleus) with fibrocollagenous tissue and inflammatory cells (lymphocytes).

Note : All biopsy specimen will be stored for 15 (fifteen) days, block and slides for 5 (five) years only from the time of receipt at the laboratory. No request ,for any of the above will be entertained after the due date.

Reference

- Rosai and Ackerman's Surgical Pathology.
- Modern Surgical Pathology.

**Gulshan Yadav, MD
Consultant Pathologist**