

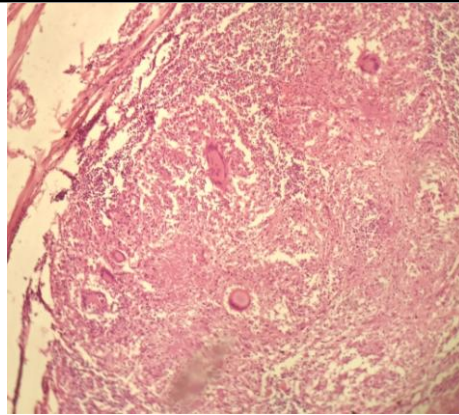
<b>Patient Name</b>	Miss. RITU	<b>Client Name</b>	Care Diagnostics Centre	<b>Specimen Received</b>	03/03/2019
<b>Age/Sex</b>	14 YRS/F			<b>Specimen Type</b>	Tissue
<b>Patient ID</b>	011903030231			<b>Collection Date</b>	03/03/2019
<b>Specimen ID</b>	MOLQ/B-335/19			<b>Report Date</b>	12/03/2019

## SURGICAL PATHOLOGY REPORT

### Submandibular lymph node.

#### DIAGNOSIS

#### TUBERCULAR LYMPHADENITIS



#### SPECIMEN

Submandibular lymph node.

#### GROSS

Received autolyzed 3.5x3.8cm greyish white tissue piece.

#### Microscopy

- Section examined shows formation of granuloma with epithelioid cells, caseous necrosis, lymphocytes and multinucleated giant cells. No malignant cells seen.

**Note :** All biopsy specimen will be stored for 15 (fifteen) days, block and slides for 5 (five) years only from the time of receipt at the laboratory. No request ,for any of the above will be entertained after the due date.

#### Reference

- Rosai and Ackerman's Surgical Pathology.
- Modern Surgical Pathology.

**Gulshan Yadav, MD**  
Consultant Pathologist