

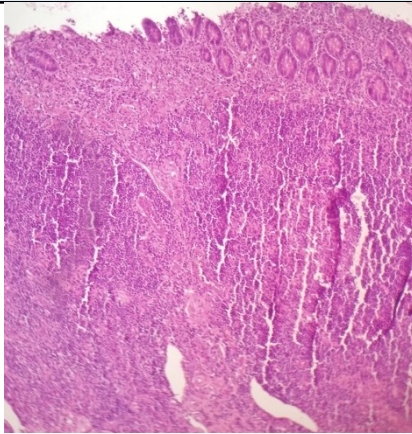
Patient Name	Mr. SUNIL-26145	Client Name	Pushpanjali Hospital (Rewari)	Specimen Received	04-Mar-2019
Age/Sex	28/M	Client Code	MolQ1789CM	Specimen Type	Tissue
Patient ID	011903040305	Ref. Doctor	DR Kuldeep	Collection Date	04-Mar-2019
Specimen ID	MOLQ/B-347/19			Report Date	08-Mar-2019

SURGICAL PATHOLOGY REPORT

APPENDIX.

DIAGNOSIS

ACUTE APPENDICITIS.



SPECIMEN

Appendix.

GROSS

Received 6x1.1cm greyish white tissue piece cut section shows fecolith.

Microscopy

- Section examined shows lymphoid follicles with ulcerative mucosa. Deeper tissue shows inflammatory cells (polymorphs and lymphocytes).

Note : All biopsy specimen will be stored for 15 (fifteen)days, block and slides for 5(five) years only from the time of receipt at the laboratory. No request ,for any of the above ,will be entertained after the due date.

Reference

- Rosai and Ackerman's Surgical Pathology.
- Modern Surgical Pathology.

Gulshan Yadav, MD
Consultant Pathologist