

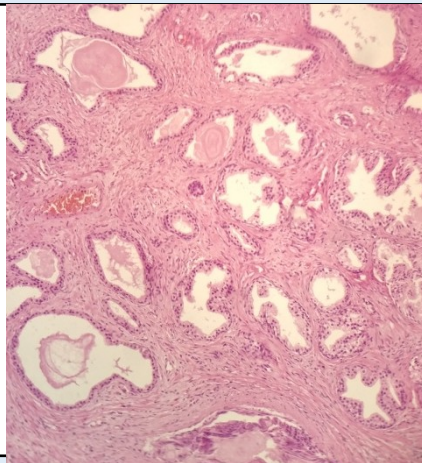
Patient Name	Mr. JAGRAM 26313	Client Name	Pushpanjali Hospital	Specimen Received	04-Mar-2019
Age/Sex	83/M		(Rewari)	Specimen Type	Tissue
Patient ID	011903040294	Client Code	MolQ1839P	Collection Date	04-Mar-2019
Specimen ID	MOLQ/B-344/19	Ref. Doc	DR.S.P YADAV	Report Date	08-Mar-2019

SURGICAL PATHOLOGY REPORT

TURP

DIAGNOSIS

BENIGN PROSTATIC HYPERPLASIA.



SPECIMEN

TURP

GROSS

Received multiple greyish white tissue piece measuring 5.5cm in aggregate.

Microscopy

- Section examined shows bilayered prostatic glands with columnar lining epithelium and with small round to oval nucleus surrounded by large number of fibrocollagenous tissue and mononuclear inflammatory cell.

Note : All biopsy specimen will be stored for 15 (fifteen)days, block and slides for 5(five) years only from the time of receipt at the laboratory. No request ,for any of the above ,will be entertained after the due date.

Reference

- Rosai and Ackerman's Surgical Pathology.
- Modern Surgical Pathology.

Gulshan Yadav, MD
Consultant Pathologist