

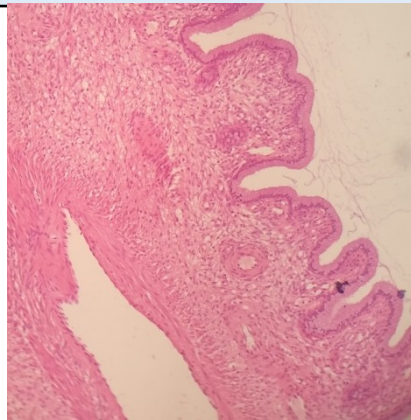
<b>Patient Name</b>	Mrs. PREM DEVI	<b>Client Name</b>	Pushpanjali Hospital (Rewari)	<b>Specimen Received</b>	04-Mar-2019
<b>Age/Sex</b>	55/F	<b>Client Code</b>	MolQ1839P	<b>Specimen Type</b>	Tissue
<b>Patient ID</b>	011903040292	<b>Ref. Doc</b>	DR.KULDEEP	<b>Collection Date</b>	04-Mar-2019
<b>Specimen ID</b>	MOLQ/B-353/19			<b>Report Date</b>	08-Mar-2019

## SURGICAL PATHOLOGY REPORT

### GALL BLADDER.

#### DIAGNOSIS

**CHOLECYSTITIS AND CHOLELITHIASIS.**



#### SPECIMEN

Gall Bladder.

#### GROSS

Received 10x3.2cm long gall bladder. Cut section shows stones..

#### Microscopy

- Section examined shows ulcerative mucosa and Rokitansky-Aschoff sinuses (irregularly shaped tubular structures lined by cuboidal lining epithelium with round to oval nucleus) with fibro collagenous tissue and inflammatory cells (lymphocytes).

**Note :** All biopsy specimen will be stored for 15 (fifteen) days, block and slides for 5 (five) years only from the time of receipt at the laboratory. No request ,for any of the above will be entertained after the due date.

#### Reference

- Rosai and Ackerman's Surgical Pathology.
- Modern Surgical Pathology.

**Gulshan Yadav, MD**  
Consultant Pathologist