

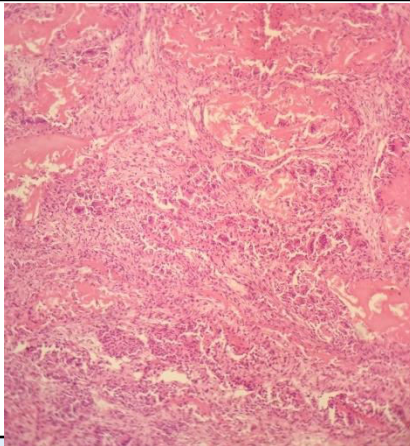
Patient Name	Mrs. SEEMA 26013	Client Name	Pushpanjali Hospital	Specimen Received	04/03/2019
Age/Sex	53 Years/Female	(Rewari)		Specimen Type	Tissue
Patient ID	011903040290	Client Code	MolQ1789CM	Collection Date	04/03/2019
Specimen ID	MOLQ/B-354/19	Ref. Doctor	DR.KIRAN	Report Date	07/03/2019

SURGICAL PATHOLOGY REPORT

Uterus

DIAGNOSIS

Leiomyoma with endometrial polyp.



SPECIMEN

Uterus

GROSS

Received 9x4.2cm uterus with cervix cut section shows multiple fibroid measuring 3x2cm with endometrial shows 4x3cm polyp with bilateral tube.

Microscopy

Section examined shows

1. Endometrium with proliferative phase.
2. Myometrium with muscle bundles.
3. Polyp shows endometrial polyp.
4. Fibroid with interlacing muscle bundles.
5. Cervix with mononuclear inflammatory cells.
6. Bilateral tube unremarkable.

Note : All biopsy specimen will be stored for 15 (fifteen) days, block and slides for 5 (five) years only from the time of receipt at the laboratory. No request ,for any of the above ,will be

Reference

- i) Rosai and Ackerman's Surgical Pathology.
- ii) Modern Surgical Pathology. Report generated at MolQ Laboratory, Gurgaon

Gulshan Yadav, MD
Consultant Pathologist