

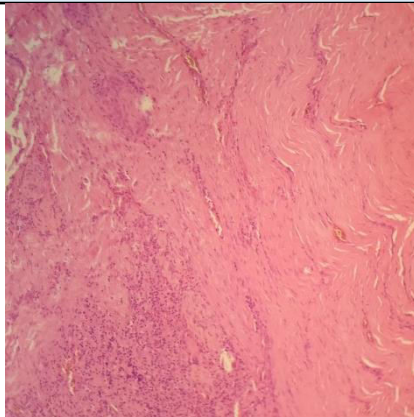
<b>Patient Name</b>	Mr. BURHAN	<b>Client Name</b>	Patients Care Clinical Laboratory	<b>Specimen Received</b>	04/03/2019
<b>Age/Sex</b>	22 Years/Male		Jammu & Kashmir	<b>Specimen Type</b>	Tissue
<b>Patient ID</b>	011903030254	<b>Client Code</b>	MolQ1839P	<b>Collection Date</b>	04/03/2019
<b>Specimen ID</b>	MOLQ/B-359/19	<b>Ref. Doc</b>	OPD (NEW GEO CLI LAB)	<b>Report Date</b>	07/03/2019

## SURGICAL PATHOLOGY REPORT

### Fistula

#### DIAGNOSIS

**Non specific inflammation.**



#### SPECIMEN

Fistula

#### GROSS

Received 3x1.1cm greyish white tissue piece.

#### Microscopy

1. Section examined shows fibro collagenous tissue blood vessels with inflammatory cells (lymphocyte, polymorphs).
2. No granuloma and no malignant cells seen.

**Note :** All biopsy specimen will be stored for 15 (fifteen) days, block and slides for 5 (five) years only from the time of receipt at the laboratory. No request, for any of the above will be entertained after the due date.

#### Reference

- i) Rosai and Ackerman's Surgical Pathology.
- ii) Modern Surgical Pathology.

**Gulshan Yadav, MD  
Consultant Pathologist**