

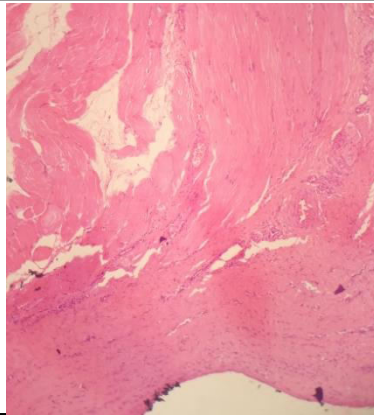
| | | | | | |
|---------------------|----------------------|--------------------|-----------------------------------|--------------------------|-------------------|
| Patient Name | Mrs. SHAKEELA | Client Name | Patients Care Clinical Laboratory | Specimen Received | 04/03/2019 |
| Age/Sex | 35 Years/Female | | Jammu & Kashmir | Specimen Type | Tissue |
| Patient ID | 011903030251 | Client Code | MolQ1839P | Collection Date | 04/03/2019 |
| Specimen ID | MOLQ/B-340/19 | Ref. Doc | YOUNUS KAMAL MS | Report Date | 07/03/2019 |

SURGICAL PATHOLOGY REPORT

Swelling of foot

DIAGNOSIS

Benign mesenchymal lesion.



SPECIMEN

Swelling of foot

GROSS

Received 4x2cm greyish white tissue piece.

Microscopy

- Section examined shows muscle bundles mature adipose cells and fibro collagenous tissue and blood vessels .

Note : All biopsy specimen will be stored for 15 (fifteen) days, block and slides for 5 (five) years only from the time of receipt at the laboratory. No request, for any of the above will be entertained after the due date.

Reference

- Rosai and Ackerman's Surgical Pathology.
- Modern Surgical Pathology.

Gulshan Yadav, MD
Consultant Pathologist