

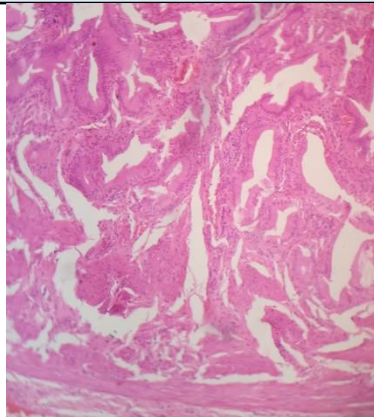
<b>Patient Name</b>	<b>Mrs. SARWA</b>	<b>Client Name</b>	Patients Care Clinical Laboratory	<b>Specimen Received</b>	<b>04/03/2019</b>
<b>Age/Sex</b>	52 Years/Female		Jammu & Kashmir	<b>Specimen Type</b>	Tissue
<b>Patient ID</b>	011903030249	<b>Client Code</b>	MolQ1839P	<b>Collection Date</b>	04/03/2019
<b>Specimen ID</b>	MOLQ/B-342/19	<b>Ref. Doc</b>	OPD (NEW GEO CLI LAB)	<b>Report Date</b>	07/03/2019

## SURGICAL PATHOLOGY REPORT

### GALL BLADDER.

#### DIAGNOSIS

**CHOLECYSTITIS AND CHOLELITHIASIS.**



#### **SPECIMEN**

Gall Bladder.

#### **GROSS**

Received 7.5x2.9cm long gall bladder. Cut section shows stones.

#### **Microscopy**

Section examined shows ulcerative mucosa and Rokitansky-Aschoff sinus (irregularly shaped tubular structures lined by cuboidal lining epithelium with round to oval nucleus) with fibro collagenous tissue and inflammatory cells (lymphocytes).

**Note :** All biopsy specimen will be stored for 15 (fifteen) days, block and slides for 5 (five) years only from the time of receipt at the laboratory. No request, for any of the above will be entertained after the due date.

#### **Reference**

- i) Rosai and Ackerman's Surgical Pathology.
- ii) Modern Surgical Pathology.

**Gulshan Yadav, MD  
Consultant Pathologist**