

<b>Patient Name</b>	Mrs. PRIMILA	<b>Client Name</b>	Prakash Hospital,	<b>Specimen Received</b>	02-Mar-2019
<b>Age/Sex</b>	45/F		Gurgaon	<b>Specimen Type</b>	Tissue
<b>Patient ID</b>	011903020159	<b>Client Code</b>	MolQ1672P	<b>Collection Date</b>	02-Mar-2019
<b>Specimen ID</b>	MOLQ/B-334-19	<b>Ref. Doctor</b>		<b>Report Date</b>	07-Mar-2019

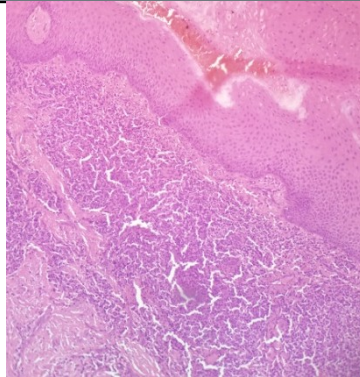
## SURGICAL PATHOLOGY REPORT

Gingival Swelling irt 11.

### DIAGNOSIS

#### IDIOPATHIC PLASMA CELL GRANULOMA

**ADVISED:** As history of hypertension is given by the clinician, it is advised that patient should consult a physicians. Follow up to be done post the medication prescribed. Also, advised for Scaling and educate the patient regarding the oral hygiene.



#### SPECIMEN

Gingival Swelling irt 11.

#### GROSS

Received 1x1 cm greyish white tissue piece.


#### Microscopy


- Section examined shows one bit of tissue with stratified squamous lining epithelium with mild hyperplasia and long slender rete pegs (few fused) overlying the connective tissue stroma.
- Connective tissue stroma shows mixed inflammatory cell infiltrate composed of typical eccentrically placed nucleus with cart wheel appearance plasma cells, arranged in sheets and in islands along with few lymphocytes, fibrocollagenous tissue. Numerous endothelial lined blood capillaries and hemorrhagic areas are also evident.

**Note :** All biopsy specimen will be stored for 15 (fifteen)days, block and slides for 5(five) years only from the time of receipt at the laboratory. No request ,for any of the above .will be entertained after the due date.

#### Reference

- Rosai and Ackerman's Surgical Pathology.
- Modern Surgical Pathology.
- Shafers 7<sup>th</sup> edition, Textbook of Oral Pathology

  
**Tina Bhardwaj, MDS**  
**Consultant Oral Histopathologist**

  
**Gulshan Yadav, MD**  
**Consultant Pathologist**