

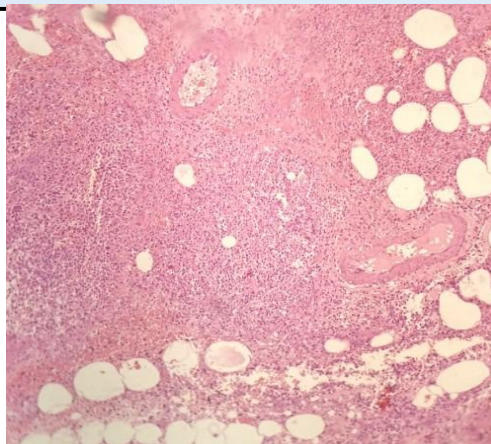
Patient Name	Mrs. DARSHAN	Client Name	Pushpanjali Hospital (Rewari)	Specimen Received	01/03/2019
Age/Sex	50 Years/Male			Specimen Type	Tissue
Patient ID	011903010277			Collection Date	01/03/2019
Specimen ID	MOLQ/B-318/19			Report Date	06/03/2019

SURGICAL PATHOLOGY REPORT

APPENDIX.

DIAGNOSIS

ACUTE ON CHRONIC APPENDICITIS



SPECIMEN

Appendix.

GROSS

Received 7.5x1.8cm long appendix with mesoappendix cut sections shows fecolith.

Microscopy

- Section examined shows lymphoid follicles with ulcerative mucosa. Deeper tissue shows inflammatory cells (polymorphs, lymphocytes and few histiocytes).

Note : All biopsy specimen will be stored for 15 (fifteen)days, block and slides for 5(five) years only from the time of receipt at the laboratory. No request ,for any of the above ,will be entertained after the due date.

Reference

- Rosai and Ackerman's Surgical Pathology.
- Modern Surgical Pathology.

Gulshan Yadav, MD
Consultant Pathologist