

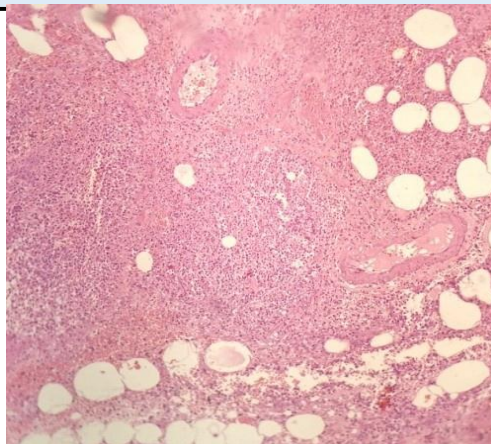
<b>Patient Name</b>	Mrs. DARSHAN	<b>Client Name</b>	Pushpanjali Hospital (Rewari)	<b>Specimen Received</b>	01/03/2019
<b>Age/Sex</b>	50 Years/Male			<b>Specimen Type</b>	Tissue
<b>Patient ID</b>	011903010277			<b>Collection Date</b>	01/03/2019
<b>Specimen ID</b>	MOLQ/B-318/19			<b>Report Date</b>	06/03/2019

## SURGICAL PATHOLOGY REPORT

### APPENDIX.

#### DIAGNOSIS

**ACUTE APPENDICITIS**



#### SPECIMEN

Appendix.

#### GROSS

Received 7.5x1.8cm long appendix with mesoappendix cut sections shows fecolith.

#### Microscopy

Section examined shows lymphoid follicles with ulcerative mucosa. Deeper tissue shows inflammatory cells (polymorphs). No Granuloma and no malignant cells seen.

**Note :** All biopsy specimen will be stored for 15 (fifteen) days, block and slides for 5 (five) years only from the time of receipt at the laboratory. No request, for any of the above, will be entertained after the due date.

#### Reference

- i) Rosai and Ackerman's Surgical Pathology.
- ii) Modern Surgical Pathology.

**Gulshan Yadav, MD**  
Consultant Pathologist