

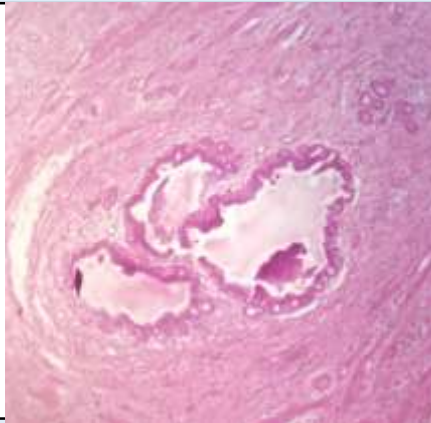
Patient Name	Mrs. PHOOLWATI-25422	Client Name	Pushpanjali Hospital (Rewari)	Specimen Received	01-Mar-2019
Age/Sex	51/F	Client Code	MolQ1839P	Specimen Type	Tissue
Patient ID	011903010282	Ref. Doc	DR.KULDEEP	Collection Date	01-Mar-2019
Specimen ID	MOLQ/B-316/19			Report Date	05-Mar-2019

SURGICAL PATHOLOGY REPORT

GALL BLADDER.

DIAGNOSIS

CHOLECYSTITIS AND CHOLELITHIASIS.



SPECIMEN

Gall Bladder.

GROSS

Received 4.8x2.1cm long gall bladder already cut open with tiny stones.

Microscopy

- Section examined shows ulcerative mucosa and Rokitansky-Aschoff sinuses (irregularly shaped tubular structures lined by cuboidal lining epithelium with round to oval nucleus) with fibro collagenous tissue and inflammatory cells (lymphocytes).

Note : All biopsy specimen will be stored for 15 (fifteen) days, block and slides for 5 (five) years only from the time of receipt at the laboratory. No request ,for any of the above will be entertained after the due date.

Reference

- Rosai and Ackerman's Surgical Pathology.
- Modern Surgical Pathology.

**Gulshan Yadav, MD
Consultant Pathologist**