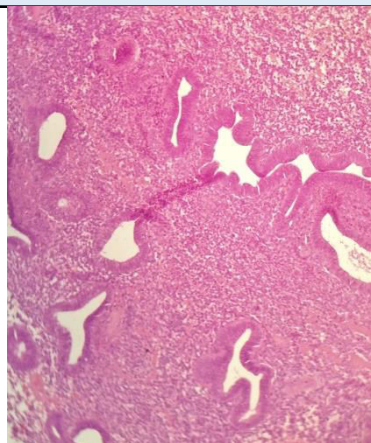


Patient Name	Mrs. BIMLA	Client Name	Civil Hospital-P	Specimen Received	01/03/2019
Age/Sex	50 Years/Female		Gurgaon	Specimen Type	Tissue
Patient ID	011903010130	Client Code	MolQ1681P	Collection Date	01/03/2019
Specimen ID	MOLQ/B-325/19			Report Date	05/03/2019

SURGICAL PATHOLOGY REPORT

ENDOMETRIUM

Simple Hyperplasia Without Atypia.



SPECIMEN

Endometrium

GROSS

Received multiple greyish white tissue piece.

Microscopy

1. Section examined shows small and dilated endometrial glands having columnar lining epithelium with round nucleus.
2. Stroma shows mononuclear inflammatory cells seen.

Note : All biopsyspecimen will be stored for 15 (fifteen) days, block and slides for 5 (five) years only from the time of receipt at the laboratory. No request for any of the above, will be entertained after the due date.

Reference

- i) Rosai and Ackerman's Surgical Pathology.
- ii) Modern Surgical Pathology.

Gulshan Yadav, MD
Consultant Pathologist