

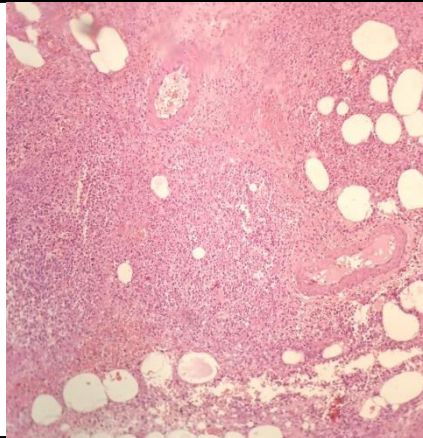
<b>Patient Name</b>	Mrs. MUNNA BAI	<b>Client Name</b>	Civil Hospital-P, Gurgaon	<b>Specimen Received</b>	01/03/2019
<b>Age/Sex</b>	35 Years/Female	<b>Client Code</b>	MolQ1681P	<b>Specimen Type</b>	Tissue
<b>Patient ID</b>	011903010013			<b>Collection Date</b>	01/03/2019
<b>Specimen ID</b>	MOLQ/B-314/19			<b>Report Date</b>	05/03/2019

## SURGICAL PATHOLOGY REPORT

### APPENDIX.

#### DIAGNOSIS

**ACUTE APPENDICITIS**



#### SPECIMEN

Appendix.

#### GROSS

Received 6.5x2.2cm long appendix .

#### Microscopy

1. Section examined shows lymphoid follicles with ulcerative mucosa. Deeper tissue shows inflammatory cells (polymorphs, lymphocytes and few histiocytes).

**Note :** All biopsys pecimen will be stored for 15 (fifteen)days, block and slides for 5(five) years only from the ti me of receipt at the laboratory. No re quest ,for any of the above ,will be entertained a fter the due date.

#### Reference

- i) Rosai and Ackerman's Surgical Pathology.
- ii) Modern Surgical Pa thology.

**Gulshan Yadav, MD  
Consultant Pathologist**