

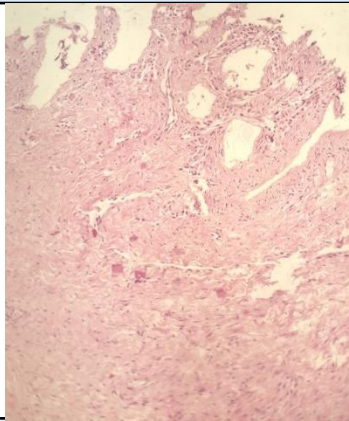
Patient Name	Mrs. REENA	Client Name	La lita Memorial Hospital Pvt. Ltd. (Rewari)	Specimen Received	28/02/2019
Age/Sex	20 Years/Female	Client Code	MolQ1652P	Specimen Type	Tissue
Patient ID	011902280323			Collection Date	28/02/2019
Specimen ID	MOLQ/B-309/19			Report Date	05/03/2019

SURGICAL PATHOLOGY REPORT

Ovary

DIAGNOSIS

Cystadenoma



SPECIMEN

Ovary

GROSS

Received Autolyzed 18x16cm cystic tissue piece cut section shows multinucleated with mucoid material.

Microscopy

1. Section examined shows stromal cells inflammatory cells with epithelial lining having small round nucleus.

No granuloma and no malignant cells seen.

Note : All biopsy specimen will be stored for 15 (fifteen) days, block and slides for 5 (five) years only from the time of receipt at the laboratory. No request, for any of the above will be entertained after the due date.

Reference

- i) Rosai and Ackerman's Surgical Pathology.
- ii) Modern Surgical Pathology.

Gulshan Yadav, MD
Consultant Pathologist